

CASE REPORT

Esthetic Management of Diastema Closure: An Innovative Technique Utilizing Putty Index Method

Rakhi Gupta¹, Anjali Miglani², Amit Gandhi³, Neha Kapoor⁴

ABSTRACT

Diastemas are one of the most common forms of malocclusion seen frequently in the midst of the maxillary central incisors. Along with midline diastema, there can be generalized spacing in anterior teeth, especially in the maxillary arch. The etiology for the same is considered to be multifactorial. These spacings lead to an unaesthetic smile, impairment of phonetics, and hindrance in maintaining oral hygiene. These can be managed either by surgical, orthodontic, periodontal, restorative, and prosthodontic procedures or by a combination of procedures to fulfill patient's esthetic and functional demands. Recent advances in direct dental composite resin, give dental practitioner an advantage to perform minimal invasive esthetic dentistry which is conservative and also less time-consuming. This article introduces a case report of esthetic management of maxillary anterior spacing including midline diastema with composite resin utilizing direct technique along with the putty index method, with supplementary lab procedures.

Keywords: Direct composite resin, Midline diastema, Putty index method

How to cite this article: Gupta R, Miglani A, Gandhi A, Kapoor N. Esthetic Management of Diastema Closure: An Innovative Technique Utilizing Putty Index Method *Int J Oral Care Res* 2018;6(1):S144-148.

Source of support: Nil

Conflicts of interest: None

INTRODUCTION

Diastema is described as space more than 0.5 mm between the teeth. It is most usual forms of incomplete occlusion present usually between the maxillary incisors than the mandibular incisors.^[1] It's a dark space between adjacent teeth that are separated from each other, with no presence of a contact area. Causes for this defect may be an extremely wide dental arch,

congenital tooth absence, anomalous tooth size, and labial frenum hypertrophy.^[2] A protocol should then be made whether to treat the diastema by means of direct restorative therapy or to treat the patient with multidisciplinary approach.^[3] There are various treatment options for esthetic management of dental spaces which include veneers and crowns, but they are invasive and noneconomical. Hence, a treatment option is sought which is both noninvasive and economical using composite resins. Recent advances in direct composite resins give the dental practitioner an advantage to perform direct bonding procedures with minimal invasive procedures on the tooth. This conservative procedure is a chairside procedure which is less time-consuming.^[4] Composite resins can duplicate the details of pellucid and opalescence.^[5] They are the foremost material of choice, furnishing natural color to teeth undetectable to human vision when applied with correct technique,^[5] thus ensuring a pleasant aspect. Another advantage of composites is that they are economical compared to ceramic materials and enables reparability.^[6]

The use of silicone index is one of the biggest game changers in dentistry for many clinicians in the anterior composite build up. The palatal silicone index is an imprint of the wax-up through which required information is transferred into the mouth during treatment.

Putty index perfectly defines the sagittal dimensions, the length, and the incisal edge position of the desired final restoration, the incisal thickness, mesial and distal line angles, the labial curvature of the restoration. Hence, the practitioner can fully concentrate on the application of composite layers. The approval of the patient is taken during the mock-up phase, and then the details are transferred to the mouth through the Silicone Index, this will reproduce the exact shape and form of the tooth. This article depicts a case report of aesthetic management of anterior teeth spacing including midline diastema using composite resin utilizing putty index method.

CASE REPORT

A 21-year-old male patient reported to the Department of Conservative Dentistry and Endodontics of our institute with the chief complaint of anterior teeth spacing in

^{1,4}Student, ²Professor, ³Professor and Head

^{1,4}Department of Conservative Dentistry and Endodontics, PDM Dental College and Research Institute, Bahadurgarh, Jhajjar, Haryana, India

Corresponding Author: Dr. Rakhi Gupta, Postgraduate Student, Department of Conservative Dentistry and Endodontics, PDM Dental College and Research Institute, Sector 3-A, Bahadurgarh, Jhajjar - 124 507, Haryana, India. Phone: +91-9899878705. e-mail: rakhigupta205@gmail.com

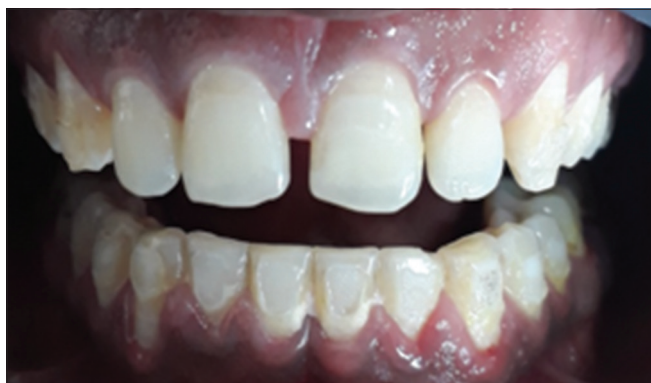

Figure 1: Pre-operative photograph

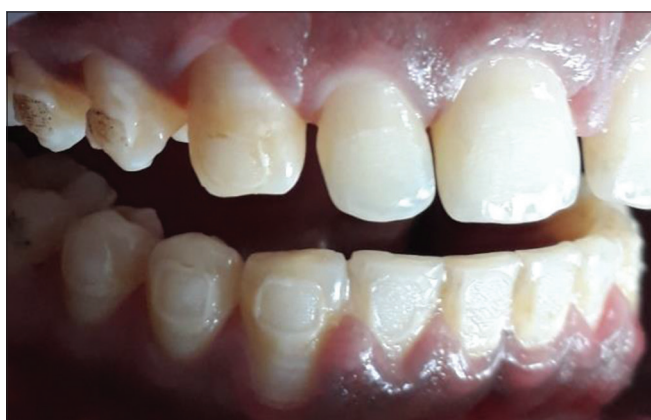

Figure 2: Pre-operative right lateral view

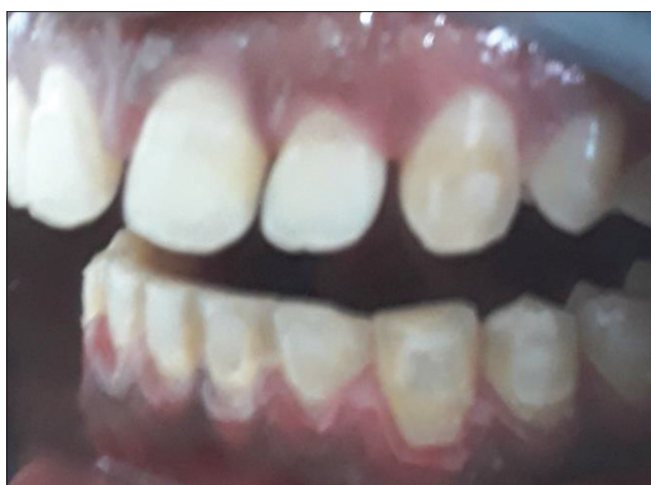

Figure 3: Pre-operative left lateral view

the upper arch. The patient gave the history of orthodontic treatment completed 1 month back for proclined and spacing in upper front teeth. However, after completion of orthodontic treatment, spaces in the anterior maxillary region along with midline diastema were still left.

Clinical examination revealed 2 mm of midline diastema in the maxillary arch along with interdental spaces (distal to central incisor and lateral incisor). The oral hygiene of the patient was satisfactory, and no significant hard and soft tissue findings were found.

Angle's Class I occlusion with normal overjet and overbite (corrected with orthodontic treatment) was noted [Figure 1-3]. The labial frenum associated with the diastema was normal in size and position. Various treatment modalities (conservative restorative and prosthetic procedures including veneers and crowns) were discussed with the patient. The patient was not willing for invasive procedures. Therefore, a minimally invasive approach with a direct composite resin restoration was planned to restore the diastema and other interdental spaces.

Clinical Technique

Maxillary and mandibular diagnostic impressions using irreversible hydrocolloid (Zelgan plus, Dentsply, India) were made and poured with dental stone. There was a scope for increasing the actual width by 1 mm on each central incisor which would close the diastema by 2 mm. Diagnostic wax-up was done on 11 and 21, and the width of 11 and 21 was increased by 1mm each by adding inlay wax on mesial sides of both the teeth which closed the diastema by 2mm. Diagnostic wax-up was done on 11, 12, 13, 21, 22, and 23 by adding blue inlay wax [Figure 4]. Palatal silicone index using the material vinyl polysiloxane (having the properties such as high reproduction of details and high final hardness) was fabricated [Figure 5]. Putty index was cut into labial and palatal aspect using the scalpel [Figure 6]. All the material that is unnecessary for the stability of matrix can also be removed using the scalpel. The most important cut is one along the incisal edge as the first layer of composite applied within the index will be the palatal with the incisal edge included. The silicone index was checked in the mouth [Figure 7]. Shades selection was done using a (VITA Tooth guide 3D Master) under natural daylight. Mesial surface of both the central incisors and proximal surfaces of lateral incisors and canines were roughened using a diamond point. Standard etching and bonding protocol were followed. Palatal silicon index was resealed, and incremental layering of direct composite resin restorative material was done on all maxillary anterior teeth. Body composite, enamel, and translucent shade composites were used in accordance with the enamel gloss and translucency of the adjacent anterior teeth. The index was used throughout the composite build-up procedure. The mesial and distal aspects are shaped using mylar strips that can be placed with the putty index on the teeth. Finishing and polishing were done using the composite polishing kit (Shofu Inc, Kyoto Japan) to achieve esthetically pleasing diastema closure [Figures 8-10]. Oral hygiene instructions were given to the patient. Finger massaging of gingival was

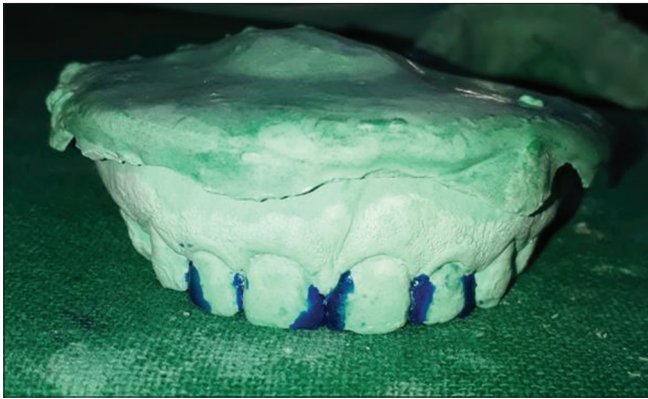


Figure 4: Wax-up of diagnostics study cast

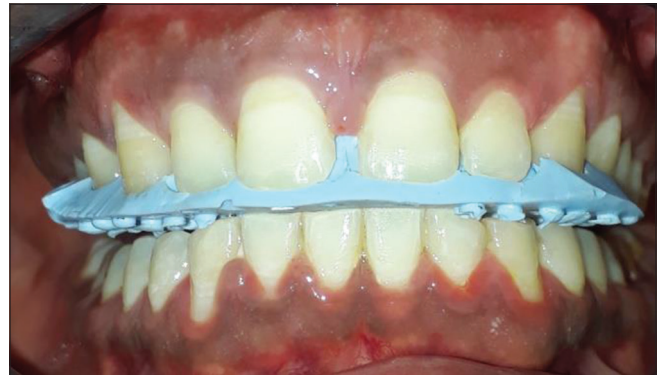

Figure 7: Palatal silicone index seated in the mouth

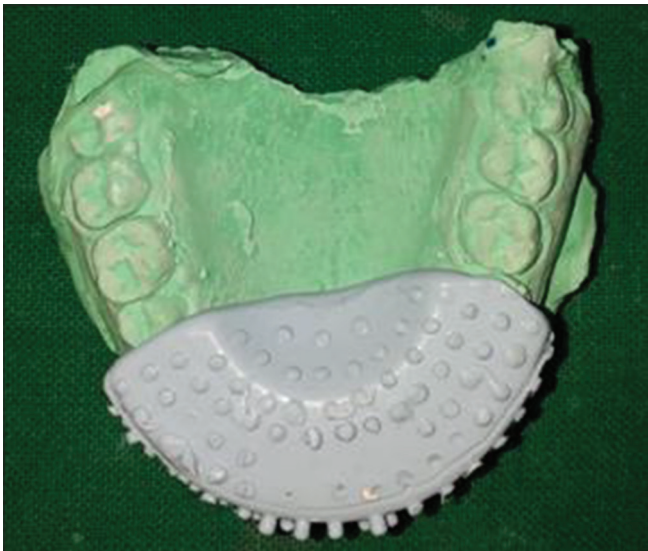

Figure 5: Fabrication of silicone index using putty

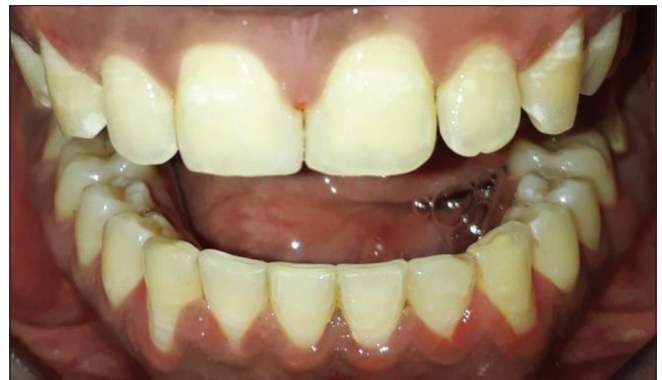

Figure 8: Post-operative view

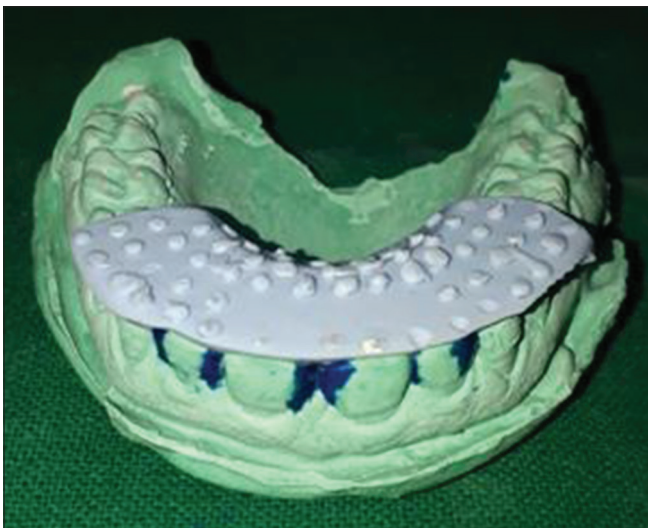

Figure 6: Putty index cut into labial and palatal aspect

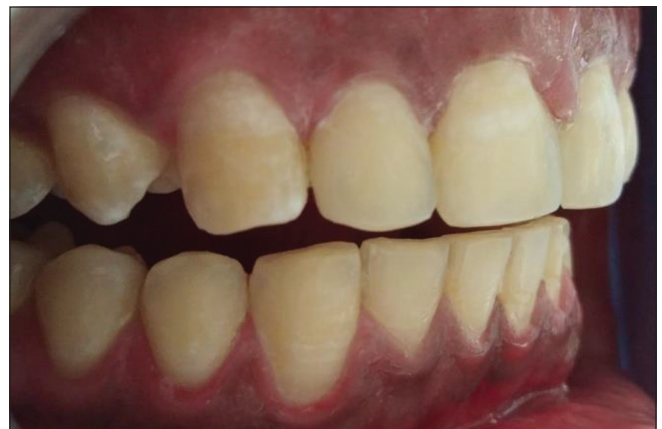

Figure 9: Post-operative right lateral view

advised for the mechanical stimulation of interdental papilla in the region of midline diastema. Figure 13 and 14 showed the difference in appearance of patient before and after the treatment respectively.

DISCUSSION

Restorative procedures may also be required after orthodontic treatment to ameliorate the aesthetics. This plan of action has been frequently taken for multidisciplinary approaches.^[7] Anterior teeth spacings including midline diastema are one such example where both orthodontic and restorative procedures are required.

For diastema closure, porcelain veneers and crowns are also one of the treatment options, but in the era of minimal invasive dentistry, the conservative approach is most preferred one. This approach is minimally

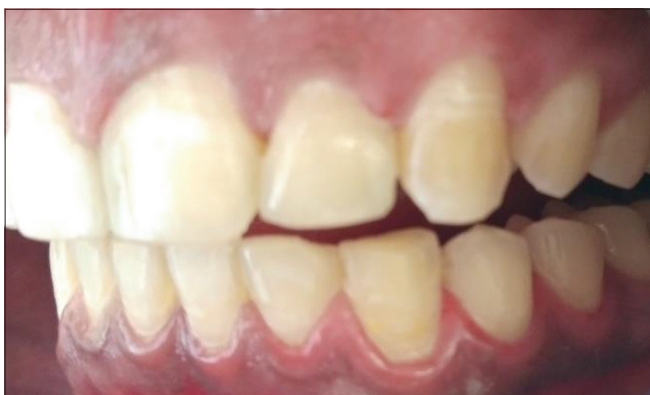

Figure 10: Post-operative left lateral view

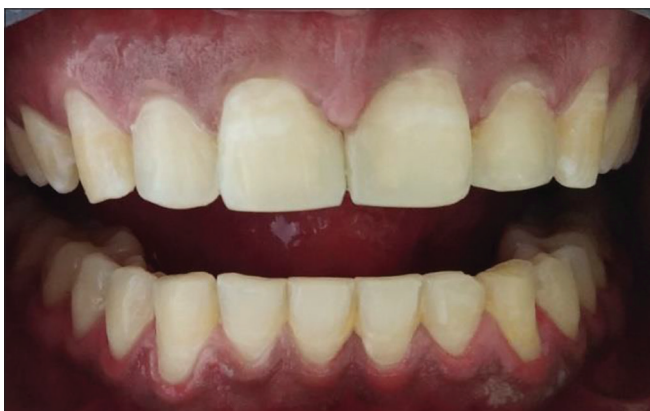

Figure 11: 6 months follow-up

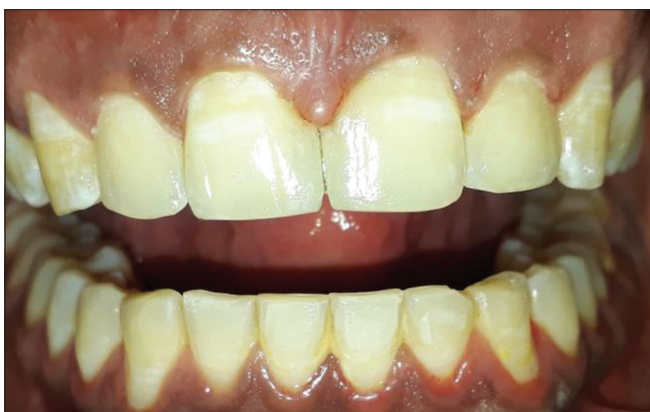

Figure 12: 1 year follow-up

invasive with excellent cosmetic results, especially in young patients.^[5] Another added advantage of these materials compared to other treatment options is that these are nonabrasive toward the opposing dentition, and they have easy reparability in case of fracture. In porcelain restorations, if any alteration is to be done, it has to be send back to the laboratory for correction.^[8,9]

The case was resolved in a single session with minimal wear of tooth structure, reproducing the excellent contour. The diastema was closed using the composite material as it was the most conservative option available and also the patient was not ready for an expensive treatment.

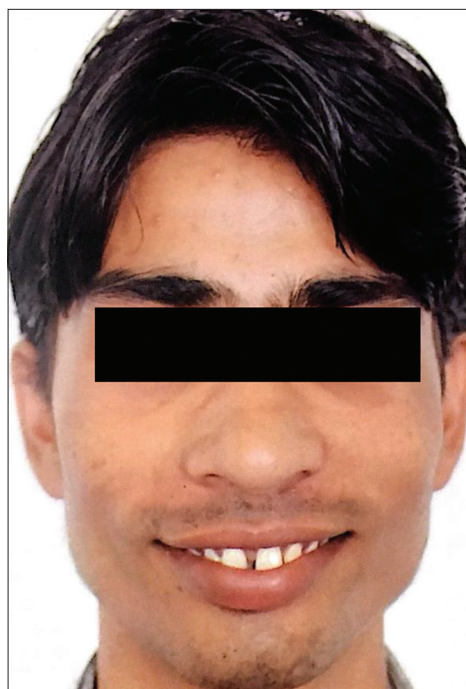

Figure 13: Pre-operative view

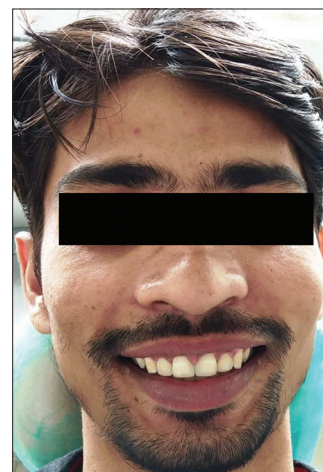

Figure 14: Post-operative view

Excellent results have been shown by various authors who have used composites for diastema closures.^[10-12] The composite material used for restorations should have proper handling (nonsticky and non-slumping) and esthetic (polishability) characteristics with high filler content and small particle size.^[13] In this case, Filtek Supreme XT with filler loading of 78.5% by weight and a filler particle size of 0.6–1.4 μm was used.^[11]

Hereby, the predictability of the direct technique was enhanced by producing a lingual incisal silicone index and allowed the creation of a stratified restoration in the mouth with the same form as a previous wax-up.

The technique is easy to perform, with creation of correct midline and optimal contact area but requires experience and skill. Rubber dam isolation is of extreme importance in placing composite restorations, but in

this case, cotton-roll isolation was considered because of two main reasons. First, with the rubber dam in place, it becomes difficult to visualize the midline of the face, so midline of face and teeth may not be coinciding.^[14] Second, it becomes difficult to adjust the palatal putty index in exact position with rubber dam present in the mouth. Diastema closure only under cotton-roll isolation has been demonstrated previously as well.^[15]

The patient was highly satisfied after seeing the esthetic result. The patient was instructed to floss before tooth brushing regularly and to avoid pigmented liquids that may cause staining of restoration. The patient was asked for regular follow-up visits 6 months [Figures 11 and 12].

CONCLUSION

The minimal invasive cosmetic approach adopted in this case satisfied the patient's demands. Esthetic Dentists should inform patients of all possible risks, benefits and alternative options before starting treatment. The natural tooth properties were replicated with maximum preservation of sound natural tissues.

ACKNOWLEDGMENT

I am thankful to Dr. Anjali Miglani and Dr. Amit Gandhi who guided me in all the ways to perform diastema closure efficiently.

REFERENCES

1. Keene HJ. Distribution of diastemas in the dentition of man. *Am J Phys Anthropol* 1963;21:437-41.
2. Brunsvold MA. Pathologic tooth migration. *J Periodontol* 2005;76:859-66.
3. Gkantidis N, Kolokitha OE, Topouzelis N. Management of maxillary midline diastema with emphasis on etiology. *J Clin Pediatr Dent* 2008;32:265-72.
4. Fahl N, Vnini L, Milnar JK. Minimally invasive dentistry and responsible aesthetics: Is this a new concept? *J Cosmetic Dent* 2010;25:16-26.
5. Nahsan FP, Mondelli RF, Franco EB, Naufel FS, Ueda JK, Schmitt VL, et al. Clinical strategies for aesthetic excellence in anterior tooth restorations: Understanding color and composite resin selection. *J Appl Oral Sci* 2012;20:151-6.
6. Kovacs BO, Mehta SB, Banerji S, Millar BJ. Aesthetic smile evaluation – A non- invasive solution. *Dent Update* 2011;38:452-4, 456-8.
7. Oliveira DD, de Oliveira BF, da Mata Cid Pinto LS, Figueiredo DS, Pithon MM, Seraidarian PI. Interdisciplinary treatment of a Class III patient with congenitally absent maxillary lateral incisors. *J Esthet Restor Dent* 2013;25:242-53.
8. Magne P, Belser UC. Porcelain versus composite inlays/onlays: Effects of mechanical loads on stress distribution, adhesion, and crown flexure. *Int J Periodontics Restorative Dent* 2003;23:543-55.
9. Berksun S, Kedici PS, Saglam S. Repair of fractured porcelain restorations with composite bonded porcelain laminate contours. *J Prosthet Dent* 1993;69:457-8.
10. Ardu S, Krejci I. Biomimetic direct composite stratification technique for the restoration of anterior teeth. *Quintessence Int* 2006;37:167-74.
11. Lenhard M. Closing diastemas with resin composite restorations. *Eur J Esthet Dent* 2008;3:258-68.
12. Araujo EM Jr., Fortkamp S, Baratieri LS. Closure of diastema and gingival recontouring using direct adhesive restorations: A case report. *J Esthet Restor Dent* 2009;21:229-40.
13. Jordan RE. *Aesthetic Composite Bonding Techniques and Materials*. 2nd ed. St. Louis, Mo, USA: Mosby-Year Book; 1993.
14. Brisman AS. Esthetics: A comparison of dentists' and patients' concepts. *J Am Dent Assoc* 1980;100:345-52.
15. Willhite C. Diastema closure with freehand composite: Controlling emergence contour. *Quintessence Int* 2005;36:138-40.